

# The Effect of the Combination of Demineralization Freeze Dried Dentin Matrix (DFDDM) and Moringa oleifera Lam to increase Fibroblasts and Osteoblasts cell in Alveolar Bone after Caviacobaya's Tooth Extraction

Arni Irawaty Djais<sup>1</sup>, Sri Oktawati<sup>1</sup>, Hasanuddin Thahir<sup>1</sup>, Muchammad Hatta<sup>2</sup>, Bayu Indra Sukmana<sup>3</sup>, Nurdiana Dewi<sup>4</sup>, Huldani<sup>5</sup>, Yayah Inayah<sup>6</sup>, Widodo<sup>7</sup>, Irene Edith Riewpassa<sup>8</sup>, Harun Achmad<sup>6</sup>, Dewiayu Dewang<sup>9</sup>

<sup>1</sup>Department of Periodontology, Faculty of Dentistry, Hasanuddin University, Makassar, Indonesia

<sup>2</sup>Department of Microbiology, Molecular Biology and Immunology Laboratory, Faculty of Medical, Hasanuddin University, Makassar, Indonesia

<sup>3</sup>Department of Dental Radiology, Faculty of Dentistry, Lambung Mangkurat University, Banjarmasin, Indonesia

<sup>4</sup>Department of Pediatric Dentistry, Faculty of Dentistry, Lambung Mangkurat University, Banjarmasin, Indonesia

<sup>5</sup>Department of Physiology, Faculty of Medicine, Lambung Mangkurat University, Banjarmasin, Indonesia

<sup>6</sup>Department of Pedodontic, Faculty of Dentistry, Hasanuddin University, Makassar, Indonesia

<sup>7</sup>Department of Dental Public Health, Faculty of Dentistry, Lambung Mangkurat University, Banjarmasin, Indonesia

<sup>8</sup>Department of Oral Biology, Faculty of Dentistry, Hasanuddin University, Makassar, Indonesia

<sup>9</sup>Professional Program Student, Faculty of Dentistry, Hasanuddin University Makassar, Indonesia

\*Correspondence Author: Professor Harun Achmad

E-mail: [harunachmader@gmail.com](mailto:harunachmader@gmail.com).

Article History:

Submitted: 19.01.2020

Revised: 22.03.2020

Accepted: 28.04.2020

## ABSTRACT

**Background:** The socket preservation has important role in alveolar bone resorption after tooth extraction. Various graft materials can be used in socket preservation must have osteoconductive, osteoinductive and osteoproliferation properties. Autogenous bone graft from dentin can be used because it has good osteoinductive and osteoconductive properties. One of the active substances of MoringaoleiferaLam is flavonoidthat have several beneficial characteristics as an anti-inflammatory. The combination of anti-inflammatory with MO extract and Demineralization Freeze Dried Dentin Matrix (DFDDM) is expected to provide a good response to bone formation.

**Aim:** To determine the potentialof combination MO and DFDDM in formation of Fibroblast and Osteoblast's cells in post extraction caviacobaya's tooth.

**Method:** The mandibular incisors of 45 Caviacobaya were extracted and divided into five groups subjected to different socket preservation treatments sequentially with MO, DFDDM, combination of MO and DFDDM, Gamacha® and polyethylene glycol (PEG). The caviacobaya were examined on days 7, 14 and 21 after which the specimens were

sacrificed and examined using an immunohistochemical technique. The resulting data were then analyzed using one-way ANOVA and Tukey's honestly significant difference tests.

**Result:** The One Way Anova test results showed a significant difference in Fibroblast and osteoblast between the groups (p<0.05) on day 7, 14 and 21 observation. The highest mean amount of OPG and lowest mean amount of RANKL were found in the third group.

**Conclusion:** Combination of MO and DFDDM can effectively generate Fibroblast and osteoblast expressions during the preservation of tooth extraction sockets.

**Keywords:** Demineralization Freeze Dried Dentin matrix (DFDDM), Moringa oleifera, Fibroblast, Osteoblast, Caviacobaya's Tooth Extraction

## Correspondence:

Harun Achmad

Department of Pedodontic, Faculty of Dentistry, Hasanuddin University, Makassar, Indonesia

E-mail: [harunachmader@gmail.com](mailto:harunachmader@gmail.com)

DOI: [10.31838/srp.2020.4.79](https://doi.org/10.31838/srp.2020.4.79)

©Advanced Scientific Research. All rights reserved

## INTRODUCTION

Tooth extraction causes biological changes such as resorption and alveolar ridge atrophy.<sup>1</sup> The resorption rate occurs faster during the first six months after extraction. Then resorption will continue to increase by 0.5-1% per year.<sup>2</sup> Loss of structure and volume of alveolar bone will affect stability, retention, and support for prostheses, as well as the placement of dental implants because the primary stability was not achieved, adequate anchoring and ideal position.<sup>3</sup>

Extraction sockets' healing is a very dynamic process; the inflammatory response is immediately activated after tooth extraction. The healing process takes about 12 to 16 weeks. About 50% of the width of the alveolar bone disappears within 12 months after extraction, and 30% (change of 3.8 mm) occurs in the first 12 weeks, mainly due to loss of buccal plate of the alveolar bone. Therefore, techniques to maintain post-extraction sockets are often researched.<sup>4</sup>

Socket preservation or ridge preservation is a procedure performed on a tooth socket to maintain the volume and

structure of bone after extraction by placing graft material that is a cellular matrix in the form of the scaffold during the bone regeneration process.<sup>5</sup> Formation of new bone from this graft material takes times; therefore it needs a time substance to accelerate the process of new bone formation.<sup>6</sup> Bone graft material based on its origin can be categorized into autografts, allografts, xenografts, and alloplasts. In the case of allograft, there is some doubt that the amount of protein needed for bone formation is needed in osteoinduction, and transmission can occur. Also, xenograft is not popular among operators because of the immune rejection response by heterologous proteins, the possibility of transmission, and large costs. As a result, there is a lot of research on the development, application, and effects of allograft, xenograft, and synthetic graft. Bone graft material that capable of replacing autogenous bone has been highly anticipated. Research by Park Sung Min et al., found that an auto tooth bone graft material is a good bone graft material with osteoconduction and osteoinduction ability to replace autogenous bone which has many weaknesses.<sup>7</sup>

Demineralized Dentin Matrix (DDM) is an organic material from dentin that has osteogenic ability.<sup>4</sup> Autograft DDM is considered an innovative material because of its composition and characteristic which are similar to the bone graft. The substances of growth factors, biocompatibility, bioabsorption, and low maintenance costs allow this material to be a realistic alternative to artificial biomaterials.<sup>4</sup>

Moringa plants or *Moringaoleifera* Lam is a plant contains bioactive substances such as vitamins, carotenoids, polyphenols, phenolic acids, flavonoids, alkaloids, glucosinolates, isothiocyanates, tannins, and saponins.<sup>8</sup> Various researchers indicated these plants have various phytochemicals, especially phytoestrogens, who have a positive effect on bones. Recent research by Zhang et al., shows that flavonoids were able to stimulate osteoblast proliferation and differentiation. Moringa leaves can inhibit the production of cytokines by macrophages (TNF- $\alpha$ ), Interleukin-6 (IL-6), and IL-8), which caused by Lipopolysaccharide (LPS). Quercetin is a part of flavonoids that can stimulate osteoblasts and increase bone formation.<sup>8</sup> The combination of anti-inflammatory Moringa leaf extract and osteoconductive and osteoinductive characteristics of the Demineralization Freeze-Dried Dentin Matrix (DFDDM) is expected to provide a good response to bone formation. Until now, bone formation after tooth extraction with DFDDM application combined with Moringa leaf extract has not been well known. Therefore, researchers are interested to examine the effect of the combination of *Moringaoleifera* Lam and DFDDM leaf extracts on the number of osteoblast cells after the extraction of guinea pigs' teeth.

## MATERIALS AND METHODS

This study was approved by the Ethics Committee of Medical Faculty of Hasanuddin University. This type of research is an experimental laboratory in experimental animals with a post-test only control group design research design. The inclusion criteria of cavia animals were male with a bodyweight of 300-350 grams, 90-120 days old, and healthy (non-dull hair, no hair loss, physically active, and have a good feed intake).

Subjects were divided into 5 groups of treatment, Group I: post-extraction sockets were given 2% dry Moringa leaf

(MO) extract (0.5-gram MO in 24-gram PEG). Group II: post-extraction sockets were given 0.5-gram DFDDM. Group III: post-extraction sockets were given a combination (0.5-gram MO in 24-gram PEG and 0.5-gram DFDDM). Group IV: post-extraction sockets were given 0.5-gram Gamacha bone graft as a positive control and Group V: post-extraction sockets were given polyglycol (PEG) as a negative control on the mandibular incisor extraction socket. Observations were made after the 7th, 14th, and 21st days post-extraction.

MO extract was obtained from Moringa leaf extraction by the maceration method conducted at the Makassar UIN Pharmacy Laboratory. Meanwhile, the manufacture of the Demineralized Freeze-Dried Dentin Matrix (DFDDM) was carried out at the Integrated Biotechnology Laboratory of the Faculty of Animal Husbandry UNHAS and the STIFA Research Laboratory in Makassar. The specimens procedure was carried out at the Biomaterial Center Installation Laboratory, and the Anatomical Pathology Laboratory at the Hasanuddin University Hospital. The study was conducted from June to October 2019.

Caviacobaya was anesthetized with ketamine 0.2 cc/ 300 g BW. Then, the mandibular incisors are extracted using a needle holder. The former extraction socket then irrigated with saline solution then be filled following the connection space according to the direction group, then do the suturing. After 7th, 14th and 21st days, Caviacobaya was executed, the lower jaw was cut and then soaked in a 70% buffered formalin solution. Then make anatomic histopathology preparations for HE staining. The osteoblasts amount was observed using a light microscope, 400x magnifications.

The results of the calculation were recorded and tabulated. After that a statistical analysis was performed with Shapiro-wilk to determine the normal distribution of the samples, then the Levene test to determine the homogeneity of the data. Furthermore, the One-way Anova test and the Tukey HSD post hoc test to learn the differences between the study groups.

## RESEARCH RESULT

Shapiro Wilk normality test results and the Levene homogeneity test show  $p > 0.05$  which means that the data is normally distributed and homogeneous so that parametric statistical tests can be performed.

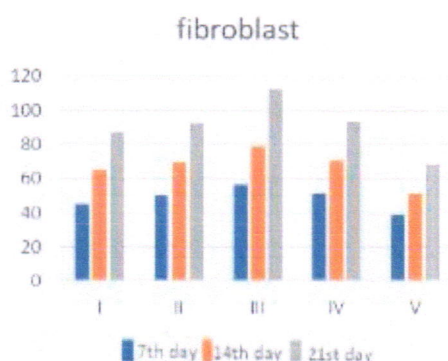


Figure 1: Graph of the average number of fibroblasts at histological observations of 7th, 14th, and 21st days

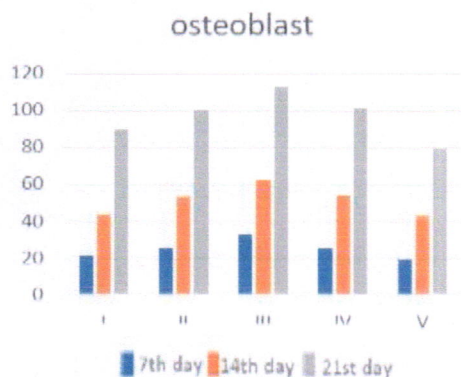


Figure 2: Graph of the average number of osteoblasts at histological observations of 7th, 14th, and 21st days

Based on the graph of the average number of fibroblasts and osteoblasts on histological observations on the 7th, 14th, and 21st days, all groups descriptively experienced an increase in the average number of fibroblasts and osteoblasts.

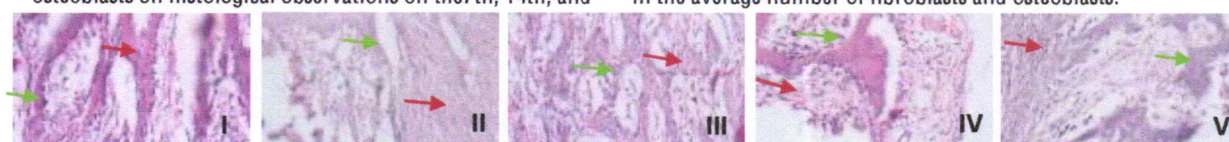


Figure 3: Red arrows show fibroblasts and green arrows show osteoblasts on immunohistochemical observations on 7th day in groups I, II, III, IV, and V

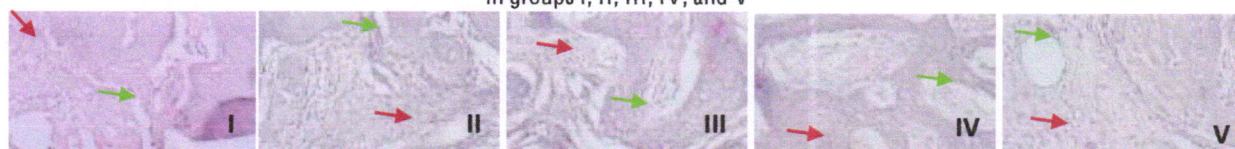


Figure 4: Red arrows show fibroblasts and green arrows show osteoblasts on immunohistochemical observations on 14th day in groups I, II, III, IV, and V.

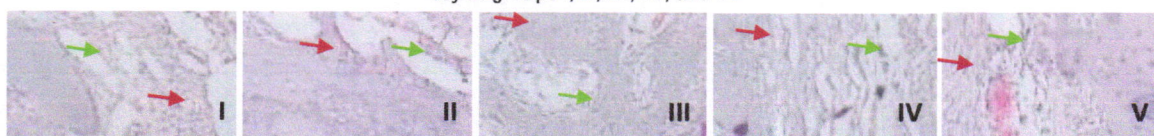


Figure 5: Red arrows show fibroblasts and green arrows show osteoblasts on immunohistochemical observations on 21st days in groups I, II, III, IV, and V

Table 1: The average number of fibroblasts and osteoblasts in the histological observation of the post tooth extraction socket

Group	N	Observation	Fibroblast ( $\bar{x} \pm SD$ )	p* value	Osteoblast ( $\bar{x} \pm SD$ )	p* value
I	3	Day 7	45.33 ± 4.04	0.00*	20.91 ± 7.31	0.00*
	3	Day 14	64.83 ± 1.89		43.16 ± 7.14	
	3	Day 21	87.66 ± 6.35		90.08 ± 8.07	
II	3	Day 7	50.33 ± 4.04	0.00*	25.41 ± 6.48	0.00*
	3	Day 14	69.83 ± 1.89		53.33 ± 5.50	
	3	Day 21	92.66 ± 6.35		100.4 ± 9.13	
III	3	Day 7	56.66 ± 7.23	0.00*	32.66 ± 3.78	0.00*
	3	Day 14	79.00 ± 4.00		62.00 ± 4.58	
	3	Day 21	112.3 ± 11.59		113.3 ± 12.50	
IV	3	Day 7	51.33 ± 4.04	0.00*	25.66 ± 3.51	0.00*
	3	Day 14	70.66 ± 2.08		54.00 ± 5.29	
	3	Day 21	93.66 ± 6.35		101.5 ± 12.08	
V	3	Day 7	38.66 ± 3.51	0.00*	19.00 ± 2.75	0.00*
	3	Day 14	51.50 ± 1.32		42.83 ± 7.14	
	3	Day 21	68.66 ± 12.05		79.33 ± 9.018	

\* Oneway Anova; p<0.05; significant

Based on table 1, the results of the OnewayAnova test showed that the number of fibroblasts and osteoblasts in all treatment groups showed a significance value of  $p < 0.05$ ,

which means that there were significant differences between each treatment group.

**Table 2:** Tukey's Honest Significant Difference (HSD) test of the average number of osteoblast fibroblast cells in histology observation at the post-extraction tooth socket

Group	Observation	Comparison	p* Fibroblast value	p* Osteoblast value
I	Day 7	Day 14	0.004*	0.026*
		Day 21	0.000*	0.000*
	Day 14	Day 21	0.002*	0.001*
II	Day 7	Day 14	0.004*	0.008*
		Day 21	0.000*	0.000*
	Day 14	Day 21	0.002*	0.000*
III	Day 7	Day 14	0.036*	0.010*
		Day 21	0.000*	0.000*
	Day 14	Day 21	0.006*	0.001*
IV	Day 7	Day 14	0.005*	0.011*
		Day 21	0.000*	0.000*
	Day 14	Day 21	0.002*	0.001*
V	Day 7	Day 14	0.158	0.012*
		Day 21	0.006*	0.000*
	Day 14	Day 21	0.063	0.001*

\* Post Hoc Tukey HSD;  $p < 0.05$ ; significant

Histological observation of the number of fibroblasts when observing on the 7th to 14th days and on the 14th to 21st days in all groups showed osteoblasts of significance value  $p < 0.05$ , meaning there was a significant difference, except in group V which had a significance value of  $p > 0.05$ .

Likewise, observations on the 7th to 14th day and 14th to 21st days in all groups showed a significance value of  $p < 0.05$ , meaning that there was a significant difference between the increase in the number of osteoblast cells on the 7th and 14th and on the 14th and 21st days after tooth extraction.

**Table 3:** Tukey's Honest Significant Difference (HSD) of the average number of expression of osteoblast histology observation at the 7th days in the mandibular incisor extraction socket

Group	I	II	III	IV	V
I		0.812	0.103	0.782	0.989
II			0.456	1.000	0.561
III				0.484	0.050*
IV					0.527
V					

\* Post Hoc Tukey HSD;  $p < 0.05$ ; significant

Based on table 3, further different tests on the 7th-day observation on histology of osteoblast socket extraction of mandibular incisors, showed a significance value of  $p < 0.05$  in the group using a combination of MO and DFDDM when compared with group V using PEG, which means there is a significant difference between the differences in

the average number of osteoblasts between group III and group V. Also, the data show a significance value of  $p > 0.05$  in the other groups, which means there is no any significant difference between the differences in the average number of osteoblasts between one treatment group and the other.

**Table 4:** Tukey's Honest Significant Difference (HSD) test of the average number of expression of osteoblast histology observation on the 14th days in the mandibular incisor extraction socket

Group	I	II	III	IV	V
I		0.304	0.022*	0.254	1.000
II			0.443	1.000	0.278
III				0.515	0.020*
IV					0.231
V					

\* Post Hoc Tukey HSD;  $p < 0.05$ ; significant

Based on table 4, further different test on the 14th-day observation on histology of osteoblast at the mandibular incisors extraction socket, group III to group I and group V show a significance value of  $p < 0.05$  which means there is a significant difference between the average difference in the number of osteoblasts between group III with respect to

group I and group V. The other groups showed a significance value of  $p > 0.05$  which means there was no significant difference between the differences in the average number of osteoblasts between one treatment group and the other.

Table 5: Tukey's Honest Significant Difference (HSD) test of the average number of expression of osteoblast histology observation on the 21st days in the mandibular incisor extraction socket

Group	I	II	III	IV	V
I		0.738	0.113	0.661	0.711
II			0.566	1.000	0.166
III				0.644	0.016*
IV					0.135
V					

\* Post Hoc Tukey HSD;  $p < 0.05$ ; significant

Based on table 5, further different test on the 21st-day observation on histology of osteoblast at the mandibular incisors extraction socket, showed a significance value of  $p < 0.05$  in group III using a combination of MO and DFDDM when compared to group V using PEG, which means there is a significant difference between the

differences in the average number of osteoblasts between group III and group V. In addition, the data show a significance value of  $p > 0.05$  in the other groups, which means there is no significant difference between the differences in the average number of osteoblasts between one treatment group and the other.

Table 6: Tukey's Honest Significant Difference (HSD) test of the average number of expression of fibroblast histology observation on the 7th days in the mandibular incisor extraction socket

Group	I	II	III	IV	V
I		0.706	0.090	0.561	0.468
II			0.514	0.999	0.049*
III				0.658	0.007*
IV					0.050*
V					

\* Post Hoc Tukey HSD;  $p < 0.05$ ; significant

Based on table 6, further different test on the 7th-day observation on histology of fibroblast at the mandibular incisors extraction socket, showed a significance value of  $p < 0.05$  in group V against groups II, III and IV which means that there are significant differences between group V with

groups II, III, and IV on the 7th day of observation. The results also showed a significance value of  $p > 0.05$  which means there was no significant difference between the average differences in the number of fibroblasts between one treatment group and the other.

Table 7: Tukey's Honest Significant Difference (HSD) test of the average number of expression of fibroblast histology observation on the 14th days in the mandibular incisor extraction socket

Group	I	II	III	IV	V
I		0.159	0.000*	0.084	0.000*
II			0.006*	0.092	0.000*
III				0.012*	0.000*
IV					0.000*
V					

\* Post Hoc Tukey HSD;  $p < 0.05$ ; significant

Based on table 7, further different test on the 14th-day observation on histology of fibroblast at the mandibular incisors extraction socket, group III to groups I, II, IV and V as well as group V against groups I, II, III, and IV showed

significance values  $p < 0.05$  which it means that there is a significant difference between the average difference in the number of fibroblasts, or having a different effect on the 14th day of observation.

Table 8: Tukey's Honest Significant Difference (HSD) test of the average number of expression of fibroblast histology observation on the 21st days in the mandibular incisor extraction socket

Group	I	II	III	IV	V
I		0.956	0.044*	0.918	0.144

II	0.126	1.000	0.050*
III		0.154	0.001*
IV			0.041*
V			

\* Post Hoc Tukey HSD; p<0.05; significant

Based on table 8, further different test on the 21st-day observation on histology of fibroblast at the mandibular incisors extraction socket, group III to group I, and V and group V to groups II, III, and IV showed a significance value of  $p < 0.05$  which means that there were significant differences between the differences in the average number of fibroblasts or having different effects on the 21st day of observation.

## DISCUSSION

In this study, the extraction of lower incisors was performed on guinea pig (caviacobaya). Caviacobaya is the most suitable experimental animal in this study because guinea pigs have an immune response similar to humans.<sup>9</sup> Socket Preservation of alveolar bone has an important role, especially after tooth extraction by placing various graft material in the newly extracted socket. Various materials that can be used are autogenous, allogeneic, xenograft, and alloplast materials, but to get satisfactory results, graft material must have osteoconduction, osteoinduction, and osteoproliferation.<sup>10</sup>

The process of bone remodeling is a process that depends on cell activity on the surface. It takes many channels that enter the alveolar bone to send blood vessels and the deeper part consists of cancellous bone and space for bone marrow. This process occurs naturally, to accelerate the process; it required innovation in tissue engineering to accelerate the process of alveolar bone remodeling.<sup>11</sup> In this study the number of fibroblasts and osteoblasts used as an indicator of bone remodeling.

Non-functional healthy teeth that have been extracted from humans are considered as infective dental waste globally. There is a high proportion of sockets that are extracted and not treated for physiological healing worldwide. In addition, there has been a reported failure of bone healing in the socket due to the absence of bone graft material.<sup>12</sup>

Autogenous bone graft has been used to repair bone defects because dentin and bone have a major characteristic, osteoinductive.<sup>13</sup> Demineralized dentin matrix (DDM) contains type-I collagen along with growth factors such as BMP-2 and fibroblast growth factors. This bioactive molecule contributes to osteoinduction and osteoconduction of human teeth as graft material. (10) Human teeth are rich in stem cell sources, matrices, trace metal ions, and growth factors. (14) Although the structure of bone tissue and dentin are different, the component ratios are similar (70% minerals, 20% collagen, 10% body fluids by weight). After demineralization, the main constituents of the dentinal matrix are type-I collagen (95%) and non-collagen proteins such as growth factors. (14) Growth factors identified in human dentin include insulin-like growth factor-I (IGF-I), skeletal growth factor/insulin-like growth factor II (IGF-II), and transforming growth factor- $\beta$  (TGF- $\beta$ ).<sup>5</sup>

In this study, the application of autograft material using Demineralized Freeze-Dried Dentin Matrix (DFDDM) autograft material observations on the 7th, 14th and 21st days (table 1) showed a significant increase in the number of fibroblasts and osteoblasts using the OnewayAnova test in the DFDDM administration group. The dentin matrix can improve the repair of mineral dentin tissue in the tooth and likewise in bone repair so that DDM can be described as representing a matrix model that is physiologically optimized to promote osteogenic signaling.<sup>15</sup> Autograft material inserted into the post-extraction socket, the results can be used as a framework for new bone growth originating from osteoblasts at the bottom of the socket.<sup>16</sup>

The results of this study also showed an increase in the number of fibroblasts and osteoblasts on observation on the 7th, 14th, and 21st days (table 1) using the OnewayAnova test in the group of Moringa leaf, *moringaoleifera* extraction. Moringa leaf extract is rich in flavonoids, saponins, alkaloids, and tannins. Flavonoids contained in Moringa leaf extract, according to research by Zhang et al., can stimulate osteoblast proliferation and differentiation.<sup>17</sup> This is also supported by Patel's research, which revealed that the administration of flavonoid substances from Moringa leaf extract can help osteoblasts differentiate, which leads to bone formation. (18) Meanwhile, saponins have an effect on osteogenic activity that promotes osteoblast proliferation and differentiation. This is also in line with recent research by Vali et al., which shows that certain flavonoids have a positive influence on bone nodule formation in vitro.<sup>19</sup> MO is rich in certain flavonoids which play an important role in stimulating osteoblastic cells. Research Wang et al., also said that flavonoids have the potential to stimulate osteoblasts.<sup>18</sup>

Besides, there is the fact that the number of osteoblasts alone is not sufficient for bone formation, therefore, combined with DDM as bone graft material to strengthen osteoblastic activity. The ideal dental bone graft must have one or more of the following characteristics: (1) osteoconductivity, to provide scaffolds that guide angiogenesis and osteogenesis; (2) osteoinductivity, to induce mesenchymal stem cells in the implant area to differentiate into preosteoblasts; and (3) osteogenicity, which contains osteoblasts that are ready to differentiate into new bone cells after implantation<sup>18</sup>

Based on the results of this study, the combination of both MO and DFDDM materials can significantly increase the number of fibroblasts and osteoblasts on days 7, 14 and 21 (tables 3-9) when compared with treatment groups I, II, IV, and V. osteoconductive and osteoinductive of both materials can increase the number of fibroblasts and osteoblasts. This occurs due to the presence of a combination of DFDDM and MO in socket preservation, DFDDM autograft has osteoinduction and osteoconductive properties of DDM (demineralized dentin matrix).

The case report by Kabir Arafat et al found that the clinical and radiographic features of the DDM graft case in the regeneration of the third molar socket gave satisfactory results, without any complications. Autogenous DDM graft material is very useful as a bone-forming material for bone regeneration in post-extraction tooth sockets. Besides, this material has low morbidity, easy handling, and large radiopacity, which allows radiographic follow-up in the area<sup>5</sup>

Besides, the presence of MO helps increase the number of fibroblasts and osteoblasts because MO has osteoinductive properties indirectly from the flavonoid content in it (quercetin) which is proven to have antioxidant properties that can stimulate osteoblast proliferation and differentiation.<sup>20</sup> Similarly, the phytoestrogen content of MO, namely estrogen which provides an anabolic effect on bones by increasing osteoblast function and inhibiting osteoclastogenesis. Estrogen action is largely mediated by the high receptor nuclear affinity and some flavonoids are considered phytoestrogens because of their ability to bind and signal through estrogen receptors.<sup>21</sup> This is consistent with research conducted by Srivastava et al. (2013), which shows that certain flavonoids such as quercetin and routine could increase osteoblast proliferation and differentiation by a simultaneous increase in osteoprogenitor production.<sup>22</sup> Similarly, when combined with a DFDDM graft material that can strengthen osteoblastic activity. Increased proliferation and osteoblastic activity will increase the number of osteoblasts and prevent osteoclastogenesis. Inhibition of osteoclastogenesis will reduce the speed and intensity of osteoclastogenesis and cause apoptosis in osteoclasts to reduce bone resorption and increase bone formation.<sup>23,24,25,26,27</sup>

Group IV as a positive control with Gamacha® showed a significant improvement from days 7, 14 and 21 because Gamacha® has good osteoinductive power.<sup>24</sup> However, this increase did not have a significant difference when compared to treatment group III. Group V as a negative control also showed an increase in the number of fibroblasts and osteoblasts. However, when compared to other treatment groups, the increase in group V had the lowest increase on observation days 7, 14 and 21 days (table 3-9).

## CONCLUSION

Giving DFDDM auto graft combination material and MO extract into the socket after tooth extraction of caviacobaya guinea pigs can increase the number of fibroblasts and osteoblasts to accelerate the process of bone remodeling and maintain alveolar bone.

## CONFLICT OF INTEREST

There is no conflict of interest in this study

## SOURCE OF FUNDING

Domestic Government

## REFERENCES

1. Garza-chapa M De, Garza-enríquez M, Chapa-arizpe MG, Israel J. (2019). Diagnosis , management and

2. Farhan A, Alani I. (2018). Multiple Techniques Have Been Proposed To Preserve Alveolar Bone after Tooth Loss. 65–8.
3. Joshi CP, Dani NH, Khedkar SU. (2016). Alveolar ridge preservation using autogenous tooth graft versus beta-tricalcium phosphate alloplast: A randomized, controlled, prospective, clinical pilot study. *J Indian Soc Periodontol.* 20(4):429–34.
4. Pagni G, Pellegrini G, Giannobile W V., Rasperini G. (2012). Postextraction alveolar ridge preservation: Biological basis and treatments. *Int J Dent.*
5. Kabir MA, Murata M, Kusano K, Akazawa T, Shibata T. (2015). Autogenous Demineralized Dentin Graft for Third Molar Socket Regeneration - A Case Report. *Dentistry.* 5(11):11–4.
6. Bayusentono S, Sumarno T. (2012). Comparison between Demineralized Bone Matrix and Freeze Dried Graft for New Bone Formation in White Rats Muscle. 40(1):24–7.
7. Park S-M, Um I-W, Kim Y-K, Kim K-W. (2012). Clinical application of auto-tooth bone graft material. *J Korean Assoc Oral Maxillofac Surg.* 38(1):2.
8. Kou X, Li B, Olayanju JB, Drake JM, Chen N. (2018). Nutraceuical or Pharmacological Potential of Moringa oleifera Lam. 10(3):343.
9. Kristiawati D. I. (2017). Introduction a Guinea Pig's Background. p. 1–3.
10. Joshi C, Dani N, Khedkar S. (2016). Alveolar ridge preservation using autogenous tooth graft versus beta-tricalcium phosphate alloplast: A randomized, controlled, prospective, clinical pilot study. *J Indian Soc Periodontol.* 20(4):429.
11. Eriksen EF. (2010). Cellular mechanisms of bone remodeling. *Rev Endocr Metab Disord.* (11):219–27.
12. F VDW, F DA, Alveolar SDE, Weijden F Van Der. (2009). Alveolar bone dimensional changes of post-extraction sockets in humans: a systematic review. 1048–58.
13. Jain S, Agrawal N, Dwivedi A, Bajaj S. (2019). A modified technique for fabrication of custom-made afterload brachytherapy appliance. *J Indian Prosthodont Soc.* 19(1):79–82.
14. Murata M, Toshiyuki A, Masaharu M, Md Arafat K, In-Woong U, Yasuhito M, et al. (2013). Autograft of Dentin Materials for Bone Regeneration. *Adv Biomater Sci Biomed Appl grafting.*
15. Avery S, Avery S, Sadaghiani L, Sloan A, Waddington R. (2017). Analysing The Bioactive Makeup Of Demineralised Dentine Matrix On Bone Marrow Mesenchymal Stem Cells For Enhanced Bone Repair. *Eur Cells Mater.* 34:1–14.
16. Soekobagiono S, Alfiandy A, Dahlan A. (2018). RANKL expressions in preservation of surgical tooth extraction treated with Moringa (*Moringa oleifera*) leaf extract and demineralized freeze-dried bovine bone xenograft. *Dent J (Dentistry Magazine).* 50(3):149.
17. Zhang D, Cheng Y, Wang N, Zhang J, Yang M, Yao X. preservation techniques of the alveolar ridge: Literature review. 5(2):462–6.

- (2008). Effects of total flavonoids and flavonol glycosides from Epimedium koreanum Nakai on the proliferation and differentiation of primary osteoblasts. 15:55–61.
18. Lin HK, Pan YH, Salamanca E, Lin Y Te, Chang WJ. Prevention of Bone Resorption by HA /  $\beta$ -TCP + Collagen Composite after Tooth Extraction: A Case Series. :1–11.
  19. Vali B, Rao LG, El-sohemy A. (2007). Epigallocatechin-3-gallate increases the formation of mineralized bone nodules by human osteoblast-like cells. 18:341–7.
  20. Patel C, Rangrez A, Parikh P. (2013). The anti-osteoporotic effect of Moringa oliefera on osteoblastic cells: SaOS 2. IOSR J Pharm Biol Sci. 5(2):10–7.
  21. Torre E. (2017). Molecular signaling mechanisms behind polyphenol-induced bone anabolism. Phytochem Rev.
  22. Srivastava S, Bankar R, Roy P. (2013). Phytomedicine Assessment of the role of flavonoids for inducing osteoblast differentiation in isolated mouse bone marrow derived mesenchymal stem cells. Eur J Integr Med [Internet]. 20(8–9):683–90. Accessed at: <http://dx.doi.org/10.1016/j.phymed.2013.03.001>
  23. Kajiya M, Giro G, Taubman MA, Han X, Mayer MPA, Kawai T. (2010). Role of periodontal pathogenic bacteria in RANKL-mediated bone destruction in periodontal disease. J Oral Microbiol. 2(2010):1–16.
  24. Achmad H, Ramadhany S, Suryajaya FE. (2019). Streptococcus Colonial Growth of Dental Plaque Inhibition Using Flavonoid Extract of Ants Nest (*Myrmecodiapendans*): An in Vitro Study. Pesquisa Brasileiraem Odontopediatria e ClínicaIntegrada. 19(1):e4250
  25. Sukmana Bayu I, Huldani, Ahmad H, Auliya H, Oktavia C, Hakim Anugrah Q, Salmah Y. (2019). The effect of periapical radiography x-ray radiation on Platelets, leukocyte, hemoglobin and mean corpuscular volume (MCV) in mice (*Mususculus*). IJPHRD. 10(11)
  26. Djais Arni I, Thahir H, Hatta M, Achmad H, Wahyuni A. (2019). Differences of minimum inhibitory concentration (MIC) and minimum bacteridal concentration (MBC) of moringa leaf extract (*Morienga Oliefera L.*) on bacteria *Aggregaticateria Actionmycetemcomitans* and *Porphynomans ginigivalis*. IJPHRD. 10(8).
  27. Achmad H, Oktawati S, Adam AM, Pasiga B, Sjahril R, Azizah A, Sukmana BI, Huldani, Siswanto H, Neormansyah I. (2020). Granulicatella adiacens bacteria isolation from periontitical patients with polymerase chain reaction techniques. Sys Rev Pharm. 11(4): 394-400.