

## Frenectomy using Two Clamps Technique: A Case Report

Arni Irawaty Djais<sup>1</sup>, Fuad Husain Akbar<sup>2\*</sup>, Mardiana Adam<sup>1</sup>, Sri Oktawati<sup>1</sup>, Hasanuddin Tahir<sup>1</sup>, Asdar Gani<sup>1</sup>, Supiaty<sup>1</sup>, Muliati Yunus<sup>3</sup>, Dwi Putri Wulansari<sup>3</sup>, Nur Indah Sari<sup>4</sup>

1. Department Periodontology, Faculty of Dentistry Hasanuddin University, Makassar, Indonesia.
2. Department Dental Public Health, Faculty of Dentistry, Hasanuddin University, Makassar, Indonesia.
3. Department Dental Radiology, Faculty of Dentistry, Hasanuddin University, Makassar, Indonesia.
4. Dental Hospital, Faculty of Dentistry, Hasanuddin University, Makassar, Indonesia.

### Abstract

Frenulum is a tissue fold or a muscle that attaches to lip and cheek on alveolar mucosa, gingiva and periosteum. Frenulum could cause orthodontic problems such as centralis diastem. The abnormal frenulum can be managed by frenectomy. In this report, we did frenectomy used two clamps technique. This case report aims to describe frenectomy using two clamps technique. A male patient aged 23 years old was referred by Department of Orthodontic, Dental Hospital of University of Hasanuddin for frenectomy due to relaps after orthodontic treatment. On clinical examination, there was a diastem on maxillary insicivus centralis and frenulum attachment on the gingiva. Then, we did frenectomy using two clamps technique, where each of clamps was used to pinched two bases of frenulum. Patient was given post surgery instruction and prescribed analgesic and mouthwash. Follow up was done one week after surgery. Frenectomy for a high frenulum's attachment using two clamps technique has a positive effect both for patient and clinician, due to its procedure is convenient in cleaning and removing frenulum.

Case report (J Int Dent Med Res 2019; 12(4): 1601-1605)

**Keywords:** Labialis frenulum, Frenectomy, two clamps technique.

**Received date:** 11 August 2019

**Accept date:** 07 May 2019

### Introduction

Diastem is a gap between two teeth that could be occurred due to frenulum attachment that reaches maxilla insicivus centralis. Frenulum is a mucosa membrane fold that attaches to lip or cheek on alveolar mucosa, gingiva and periosteum. Frenulum located on maxillary insicivus anterior is called superior labialis frenulum. A high superior labialis frenulum attachment could cause centralis diastem that disturbed esthetic, thus it is indicated for frenectomy.<sup>1-5</sup>

An abnormal superior labialis frenulum can cause centralis diastem so that inhibit the movement of orthodontic appliances. There is a correlation between a high frenulum attachment with centralis diastem that is considered as a major causing for centralis diastem. An abnormal frenulum could be a causing factor for a

persistent centralis diastem, however, it could be removed by frenectomy.<sup>6-9, 11</sup>

Frenectomy is a procedure for a high frenulum attachment with aims to repair esthetic due to centralis diastem. Frenectomy is differentiated from frenotomy based on surgical procedure. Frenectomy is a procedure that remove all frenulum, whereas frenotomy is a frenulum incision's procedure.<sup>2, 4-6</sup>

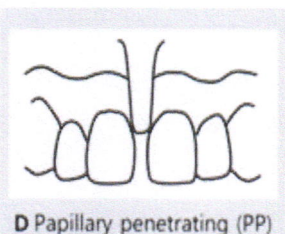
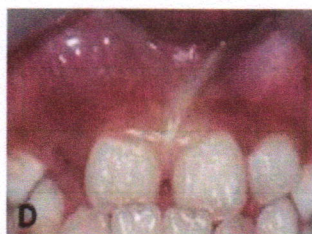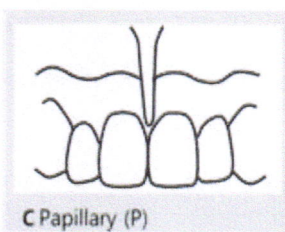
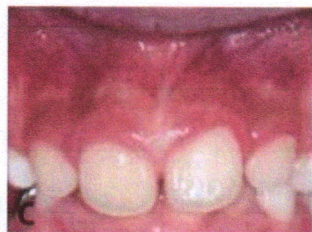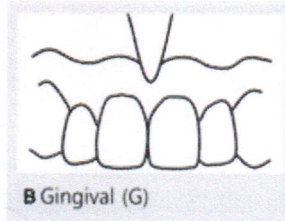
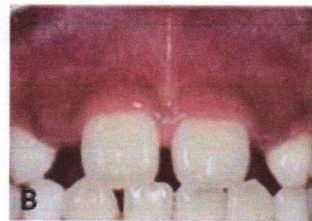
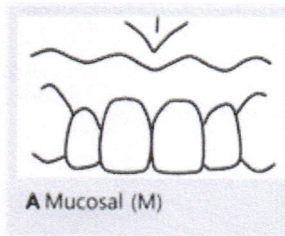
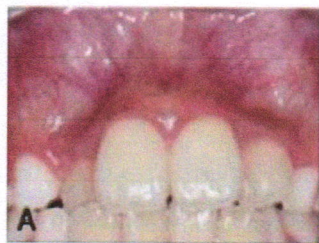
Labial frenulum attachment is classified by Placek dkk (1974), as follow:<sup>2, 4, 6, 7</sup>

1. Mucosa: Frenulum attaches to mucogingival junction.
2. Gingiva: Frenulum reaches gingiva's attachment.
3. Papilla: Frenulum's attachment expanded into interdental papilla.
4. Papilla penetration: frenulum pass into alveolar process and expanded into papilla palatina.

When frenulum is pathologic, it is indicated to be removed when frenulum's attachment cause centralis diastem and also for an abnormal frenulum with unproper gingiva and a shallow vestibule.<sup>2, 4, 7</sup>

#### \*Corresponding author:

Fuad Husain Akbar  
Department Dental Public Health,  
Faculty of Dentistry, Hasanuddin University,  
Makassar, Indonesia.  
E-mail: fuadgi2@gmail.com



### Case Report

A-23 years old male was referred by Department of Orthodontic, Hasanuddin University Dental Hospital for frenectomy. On clinical examination, there was a diastem on maxilla centralis incisivus and a labial frenulum's attachment on gingiva. Patient had been an orthodontic treatment 1.5 years ago then relapsed. Recently, patient had re-orthodontic treatment and based on decision, the patient needed a frenectomy.

### Case Management

#### Armamentarium:<sup>4</sup>

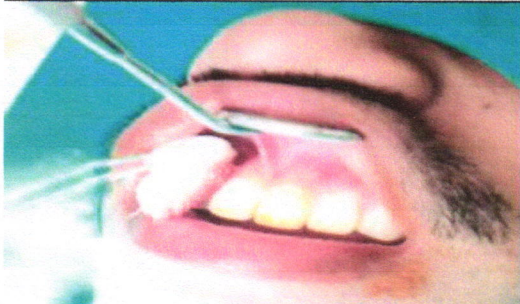1. *Clamp*, is a common surgical instrument to control bleeding. In this report, we used 2 clamps for frenectomy

2. *Blade no.15 c*, has a small curved edge and an ideal blade for a short incision
3. *Blue Nylon 4-0*, surgical suture to resist tissues after surgical
4. *Needle holder*, is a hemostat-like instrument to hold surgical needle for wound closure during suturing
5. *Tissue's scissor*, to cut tissues during surgical procedure
6. *Tissue's twizzer*, to pinch tissue during dissection and wound suturing
7. *Raspatorium*, to detach mucosa and periosteum from bone
8. *Periodontal pack*, a material that applied for wound closure after periodontal surgical
9. *Gauze ball*, a gauze filled with cotton and function as absorption tool

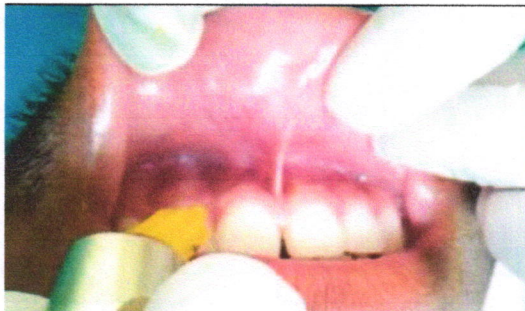Clinical examination was done to evaluate frenulum's attachment and its expansion toward palatal. Then, surgical procedure was done, as follow:<sup>2,4,5,7,13</sup>

1. Surgical area was desinfected with iodine solution then local anesthesia was done with septocaine (See Picture 1), articaine (4%), epinefrin 1:100.00
2. Local anesthesia was done using oralject to infiltrated frenulum and vestibule area on labial surface, and also palatal area near incisivus foramen (see Picture 2)
3. After the area was anesthetized, one clamp was placed attach to upper lip and the other one was placed attach to maxilla gingiva. Both of frenulum's bases on superior and inferior were pinched using clamp (see Picture 3)
4. Frenulum was excised by scalpel attached to clamp from distal direction towards to the floor of vestibule (see Picture 4)
5. All of frenulum's attachment on labial portion to palatal and tissues were removed using raspatorium and tidied up using tissue's scissors (see Picture 5)
6. Surgical area was cleaned and irrigated
7. The wound was sutured using simple suture technique (see Picture 6)
8. Wound closure was done using periodontal pack and patient was prescribed with analgesic and mouthwash (see Picture 7)

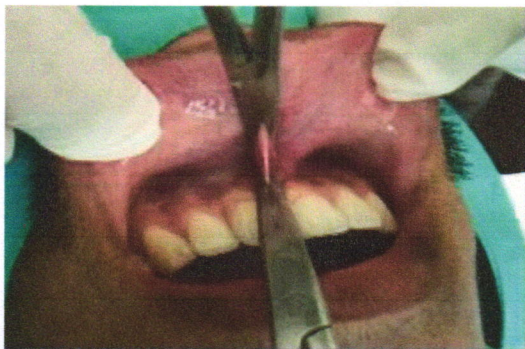
9. Periodontal pack and suturing were removed one week after surgical (see Picture 8)



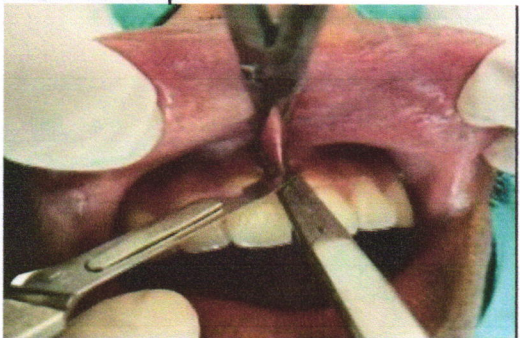
**Figure 1.** Surgical area was desinfected using iodine solution.



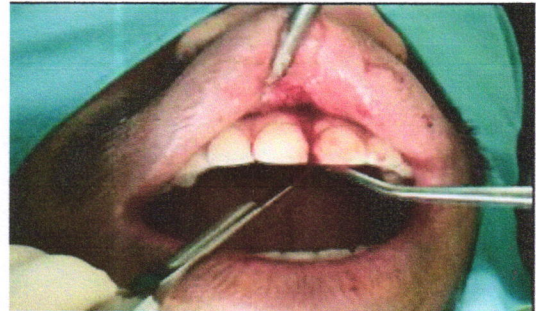
**Figure 2.** Local anesthesia using septocaine.



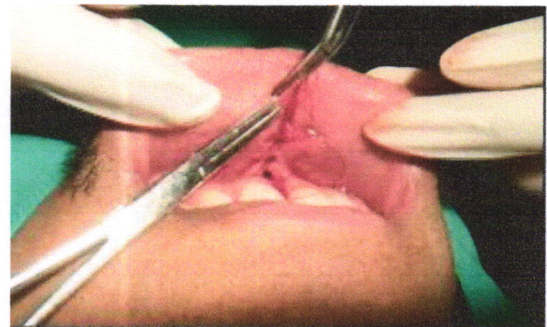
**Figure 3.** Clamp was placed parallel to frenulum and attached to lip.



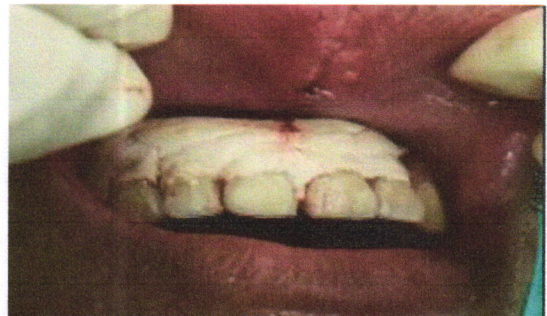
**Figure 4.** Incision was done using blade no.15 parallel to clamp.



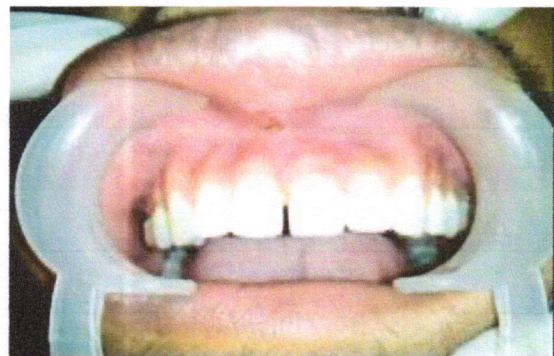**Figure 5.** Frenulum'attachment from labial to palatal portion were removed.



**Figure 6.** The wound was sutured using interrupted suture.



**Figure 7.** Wound closure was done using periodontal pack.



**Figure 8.** Periodontal pack and suturing were removed one week after surgical.

## Discussion

Relaps is a tendency of the teeth towards to its initial position before orthodontic treatment. Centralis diastem is a malocclusion with a high relaps tendency after orthodontic treatment, some of its tendency is related to an abnormal labial frenulum. Edwar (1977) found that 84% diastem relaps had a strong correlation with an abnormal labial frenulum. An abnormal frenulum as a causing for centralis diastem was supported by Huang and Creath and Kumer et al (2014). Some researches have found that an abnormal labial frenulum could cause a diastem. A high frenulum's attachment needs a surgical intervention. Based on Kumar et al. (2014), it was consisted of centralis diastem correction, almost half of patient had a surgical correction included frenectomy. Huang and Creath stated that an effective diastem treatment needed a surgical procedure to corrected the ethiology before doing orthodontic treatment.<sup>1, 3, 10-12</sup>

Frenectomy is a procedure for a high frenulum's attachment with aims to repair esthetic due to centralis diastem. Frenectomy was differentiated from frenotomy based on surgical procedure. Frenectomy is a procedure that remove all frenulum to underlined bone to correct maxilla centralis diastem, whereas, frenotomy is a frenulum's incision, that is a procedure that transfer frenulum's attachment position to create an attached gingiva area between gingiva margin with frenulum.<sup>2, 4-6, 13</sup>

Frenectomy can be done with conventional technique using scalpel. This technique was introduced by Archer (1961) and Kruger (1964), this technique was recommended for an abnormal centralis diastem and to remove muscle fiber that connect orbicularis oris to papilla palatina. This technique is a frenectomy with excision that included interdental tissue, papilla palatina and frenulum.<sup>4</sup>

In this case, frenectomy was done using two clamps technique, modified from conventional technique, this technique does not cause a wide wound on lip mucosa, due to orbicularis oris muscle's straight to lateral was resisted by clamps. This method could decrease bleeding and wound expansion during frenectomy with conventional technique. The surgical procedure without any bleeding will give a positive impact on patient and clinicians' psychics. Clinicians will be quieter and more

convenient during fibrous and frenulum cleaning procedure. Beside that, this technique could minimize scar tissue formation, give a good color to gingiva and also without any scar due to anesthesia. This simple technique could be done and give an excellent esthetic result.<sup>5, 14, 15</sup>

## Conclusion

Frenectomy for a high frenulum's attachment using two clamps technique has advantages, that are: minimize bleeding during surgical, give a positive impact to patient and clinician's psychic, cause its management is quieter and more convenient during cleaning steps after removing frenulum, beside that, this technique is economical cause uses simple instruments.

## Conflict of Interest

The authors declare that there is no conflict of interest regarding the publication of this article.

## References

1. Junior RM, Gueiros LA, Silva IH, Carvalho AA, Leao JC. Labial frenectomy with Nd:YAG laser and conventional surgery: a comparative study. *Lasers Med Science* 2013.
2. Bagchi SS, Sarkar P, Bandyopadhyay P. Management of Aberrant Frenum: Series of Cases. *Annals Appl Bio-Sci* 2016;3:34-9.
3. Yongchun Yu, Jie Sun, Wenli Lai, Taixiang Wu, Stephen Koshy, Zongdao Shi. Interventions for managing relapse of the lower front teeth after orthodontic treatment. *Cochrane Collaboration* 2013;9:1-19.
4. Devishree, Gujari SK, Shubhashini PV. Frenectomy: A Review with the Reports of Surgical Techniques. *J Clin Diagn Res* 2012;6:1587-92.
5. Butchibabu K, Koppolu P, Mishra A, Pandey R, Swapna LA, Uppada UK. Evaluation of patient perceptions after labial frenectomy procedure: A comparison of diode laser and scalpel techniques. *Eur J Gen Dent* 2014;3:29-33.
6. Patel RM, Varma S, Suragimath G, Abbayya K, Zope SA, Kale V. Comparison of labial frenectomy procedure with conventional surgical technique and diode laser. *J Dent Lasers* 2015;9:94-9.
7. Kaur G, Malik S, Grover D, Sharma A. Surgical Management of Aberrant Labial Frenum Using Modified Z-Frenuloplasty: A Case Report. *JSS Case Rep Rev* 2015;1:5-10.
8. Irvina D, Harini SS. Perawatan Diastema Sentral akibat Tingginya Perlekatan Frenulum Labialis Rahang Atas. *Indonesian J Dent* 2007;14:27-34.
9. Mohan R, Soni PK, Krishna MK, Gundappa M. Proposed classification of medial maxillary labial frenum based on morphology. *Dent Hypotheses* 2014;5:16-20.
10. Morais JF, Freitas MR, Freitas KMS, Janson G, Branco NC. Postretention stability after orthodontic closure of maxillary interincisor diastemas. *Appl Oral Sci* 2014;22(5):409-15.
11. Abdulateef DS, Ali AJ, Othman NF. The prevalence and etiology of maxillary midline diastema among orthodontic patients attending Shorsh Dental Clinic in Sulaimani City. *Sulaimani Dent J* 2014;1:86-90.

12. Nagalakshmi S, Sathish R, Priya K, Dhayanithi D. Changes in quality of life during orthodontic correction of midline diastema. *J Pharm Bioallied Sci* 2014;6:162-4.
13. Desai AJ, Bedi S, Gowda TM, Thomas R, Mehta DS. Bilateral pedicle approach for esthetic management of upper labial frenum. *J Interd Dent* 2015;5:27-30.
14. Suryono. Incision Below The Clamp sebagai Modifikasi Teknik Insisi pada Frenektomi untuk Minimalisasi Perdarahan, *J Dent* 2011;2:187-90.
15. Hungund S, Dodani K, Kambalyal P, Kambalyal P. Comparative Results of Frenectomy by Three Surgical Techniques-Conventional, Unilateral Displaced Pedicle Flap and Bilateral Displaced Pedicle Flap. 2013;4:2-6.