

Effect of the Combination of Demineralization Freeze Dried Dentin Matrix (DFDDM) and Moringa Oleifera Lam on Nuclear Factor Kapa B as a Marker of Bone

Arni Irawaty Djais¹, Sri Oktawati¹, Hasanuddin Thahir¹, Muchammad Hatta², Bayu Indra Sukmana³, Nurdiana Dewi⁴, Huldani⁵, Yayah Inayah⁶, Widodo⁷, Irene Edith Riewpassa⁸, Harun Achmad⁹, Dewiyayu Dewang⁹

¹Department of Periodontology, Faculty of Dentistry, Hasanuddin University, Makassar, Indonesia

²Department of Microbiology, Molecular Biology and Immunology Laboratory, Faculty of Medical, Hasanuddin University, Makassar, Indonesia

³Department of Dental Radiology, Faculty of Dentistry, Lambung Mangkurat University, Banjarmasin, Indonesia

⁴Department of Pediatric Dentistry, Faculty of Dentistry, Lambung Mangkurat University, Banjarmasin, Indonesia

⁵Department of Physiology, Faculty of Medicine, Lambung Mangkurat University, Banjarmasin, Indonesia

⁶Department of Pedodontic, Faculty of Dentistry, Hasanuddin University, Makassar, Indonesia

⁷Department of Dental Public Health, Faculty of Dentistry, Lambung Mangkurat University, Banjarmasin, Indonesia

⁸Department of Oral Biology, Faculty of Dentistry, Hasanuddin University, Makassar, Indonesia

⁹Professional Program Student, Faculty of Dentistry, Hasanuddin University Makassar Indonesia

*Correspondence Author: Professor Harun Achmad

E-mail: harunachmader@gmail.com.

Article History:

Submitted: 19.01.2020

Revised: 22.03.2020

Accepted: 28.04.2020

ABSTRACT

Background: The socket preservation has important role in alveolar bone resorption after tooth extraction. Various graft materials can be used in socket preservation must have osteoconductive, osteoinductive and osteoproliferation properties. Autogenous bone graft from dentin can be used because it has good osteoinductive and osteoconductive properties. One of the active substances of Moringaoleifera (MO) is flavonoidsthat have several beneficial characteristics as an anti-inflammatory. The combination of anti-inflammatory with MO extract and Demineralization Freeze Dried Dentin Matrix (DFDDM) is expected to provide a good response to bone formation.

Aim: To determine the potentialof combination Moringaoleifera and DFDDM in formation of OPG and RANKL expression post extraction caviacobaya's tooth.

Method: The mandibular incisors of 45 Caviacobaya were extracted and divided into five groups subjected to different socket preservation treatments sequentially with MO, DFDDM, combination of MO and DFDDM, Gamacha® and polyethylene glycol (PEG). The caviacobaya were examined on days 7, 14 and 21 after which the specimens were

sacrificed and examined using an immunohistochemical technique. The resulting data were then analyzed using one-way ANOVA and Tukey's honestly significant difference tests.

Result: The One Way Anova test results showed a significant difference in OPG and RANKL between the groups ($p < 0.05$) on day 7, 14 and 21 observation. The highest mean amount of OPG and lowest mean amount of RANKL were found in the third group.

Conclusion: Combination of MO and DFDDM can effectively generate OPG and RANKL expressions during the preservation of tooth extraction sockets.

Keywords: Demineralization Freeze Dried Dentin matrix (DFDDM), Moringa oleifera, Nuclear Factor Kapa B, Bone Remodeling

Correspondence:

Harun Achmad

Department of Pedodontic, Faculty of Dentistry, Hasanuddin University, Makassar, Indonesia

E-mail: harunachmader@gmail.com

DOI: [10.31838/srp.2020.4.78](https://doi.org/10.31838/srp.2020.4.78)

©Advanced Scientific Research. All rights reserved

INTRODUCTION

Tooth extraction is a surgery involving bone tissue and soft tissues in the oral cavity. The tooth extraction rate in Indonesia is still relatively high. Along with the oral health problems of Indonesian society, this matter is still in the alarming category. ¹ the dental caries index of Indonesian society from one adult with 32 teeth, the average of the damaged teeth is 7.¹

Tooth extraction causes injury or trauma and will make a cavity in the form of a tooth socket. After tooth extraction, the alveolar bone will be resorbed which causes continuous changes in the shape and size reduction in the alveolar bone.² The alveolar bone shape changes not only occur on the surface of the alveolar bone in the vertical direction but also in labio-lingual/palatal direction from the initial position that causes alveolar bone to become low, rounded, or flat.³

The process of bone healing through a phase similar to wound healing in general. The healing process in the former tooth extraction sockets involving the soft tissue healing process, which is the connective tissue and the gingival epithelium and the alveolar bone-hard tissue ie. the stages of alveolar bone regeneration consists of the inflammatory,

reparative, and remodeling phase. In these phases, osteogenesis, osteoinduction, osteoconduction, and angiogenesis processes occur. Inflammatory and proliferation phase in the bone healing lasts about 6-8 weeks, the remodeling phase lasts until several months or year.⁴ The inflammatory phase occurs immediately after the onset of injury includes the occurrence of vasoconstriction and the release of inflammatory mediators. The proliferative phase characterized by the formation of granulation tissue composed of fibroblasts and angiogenesis.⁵

In general, the wound after tooth extraction will heal by itself, but it will lead to the resorption of alveolar bone. Bone resorption is a complex morphological process associated with the erosion of bone surfaces and multinucleated giant cells (osteoclasts). Osteoclasts are derived from hematopoietic tissue and formed by the union of mononuclear cells⁶. Active osteoclast results in an increasing a lot of hydrolytic enzymes that are secreted in the border area. These enzymes damage the organic part of the bone. Osteoclast activity and morphology of the border can be modified and regulated by hormones such as parathormone and calcitonin which have receptors on the membrane of osteoclast.⁶

The balance of the bone resorption and the bone deposition is determined by the activity of two types of main cells, osteoclasts, and osteoblasts. (Now & Nandeesh, 2012) The alveolar bone resorption process begins with the bond between Receptor Activator of Nuclear Factor kappa B Ligand (RANKL) and the RANK receptor on preosteoclasts. RANKL /RANK are key in the regulation of the osteoclastogenesis process. Osteoclast formation is also influenced by proinflammatory cytokines, such as Tumor necrosis Factor- α (TNF- α), interleukin-1 (IL-1) and interleukin-6 (IL-6). The osteoclast resorption mediation process usually takes about 1-4 weeks. (Now & Nandeesh, 2012), (Dental, Djulaeha, Hendrijantini, & Pudijanto, 2016) Osteoprotegerin (OPG) has a role to protect the bone from excessive resorption by binding to RANKL so it didn't bind RANKL to RANK. RANKL and OPG bonds are a major determinant of bone mass and bone strength.⁷

The regeneration of the alveolar bone involves various biochemical, physiological, cellular, and molecular processes so that dentists need to arrange a framework as a clinical base consideration to optimize the response of bone formation. One method of the alveolar bone regeneration these days is bone graft, which includes autograft, allograft, and xenograft. Autograft (bone from the patient himself), allograft (bone from another human donor) and xenografts (animal bones). The autograft weakness is, it's often causes complications in wound healing, additional surgeries, painful feeling for the donor and inadequate bone supply to fill the gap. While the allograft and the xenograft associated with infection, inflammation and rejection reaction, which can increase the risk of the infectious diseases between species⁸

That biochemical similarity of dentin and bone made them could be considered as bone regenerative material. Demineralized Dentin Matrix (DDM) is an organic material derived from dentin that has the osteogenic capability⁹ Dentin is a suitable scaffold for tissue manipulation of teeth and can provide a combination or concentration of bioactive proteins that appropriate to accommodate the formation of odontogenic cells. Freeze drying is a possible strategy to treat dentin because it can provide long-term stability of biopharmaceutical products and improve the stability of the dentin itself. Results of previous studies show that the Freeze-Dried Dentin Matrix (FDDM) has a mechanical and biological characteristic that similar to dentin. Histologically research results show that FDDM, similar to dentin, supports dentin tissue regeneration in vivo that can be seen from the dentin-forming compounds, such as dentin sialoprotein and alkaline phosphatase¹⁰

Moringa plant (*Moringaoleifera*), included in the Moringa family and Moringa genus. Moringa contains extraordinary phytonutrients that directly support the body's efforts to inhibit and modulate enzyme that manifests pain, contains natural COX-2 inhibitor such as acid caffeoylquinic, kaempferol and quercetin in abundant quantities (Krisnadi, 2015). Quercetin which is part of Moringa leaves flavonoids could be involved in a decrease of the inflammatory process by blocking the action of a neutral factor-kappa beta (NFkB). Quercetin can stimulate osteoblasts and increase bone formation. Moringa leaves can inhibit cytokine

production by macrophages (Tumor Necrosis Factor-alpha (TNF- α), interleukin-6 (IL-6) and IL-8)), which is caused by Lipopolysaccharide (LPS). Other studies have reported that the concentration of Moringa leaves can reduce gene expression and production of inflammatory markers in macrophages. Moringa leaf extract can stimulate cellular and humoral immune response through an increase in white blood cells, neutrophils, and serum immunoglobulins¹¹ Moringa also contains minerals such as Calcium, Chromium, Copper, Fluorine, Iron, Manganese, Magnesium, Molybdenum, Phosphorus, Potassium, Sodium, Selenium, Sulfur, Zinc¹²

The anti-inflammatory combination of Moringa leaf extract and osteoconductive and osteoinductive characteristics of the Demineralized Freeze-Dried Dentin Matrix (DFDDM) is expected to bring a good response to the bone formation. Based on the above explanation, this study aims to determine the formation of an immune response of the Nuclear Factor-kappa B (NFkB) in alveolar bone after tooth extraction at guinea pigs with the combinations of Moringa leaf extract (MO) and Demineralized Freeze-Dried Dentin Matrix (DFDDM).

MATERIALS AND METHODS

Type and design of the study

This research is an experimental research laboratory with a research design using a post-test only control group design

Location and time of the study

The research was conducted in June to October in the Chemistry Laboratory and Biopharmaca Laboratory of Pharmacy faculty of Hasanuddin University, Pharmaceutical Laboratories of UIN Makassar, Makassar STIFA Research Laboratory, Faculty of Animal Biotechnology Laboratory Integrated UNHAS, Installation Laboratory Center for Biomaterials and UNHAS RSPTN Pathology Laboratory.

Research procedure

This study uses instruments and materials for moringa leaf extract 2% manufacture, DFDDM manufacture; Instruments and materials for dental extractions; instruments for DFDDM applications; instruments for Moringa leaf extract and DFDDM application at the former revocation sockets, and tools for the immunohistology examinations, polyclonal anti-OPG, and anti-RANKL materials.

This research subjects using 15 guinea pig (*Caviacobaya*), 300-350 grams, 90-120 days old, male, and healthy (non-dull hair, no hair loss, physically active, and have a good feed intake). This research has been accepted by the ethics committee of the medical faculty at Hasanuddin University.

This study begins with the extraction of moringa oleifera leaves by maceration method, using ethanol 70% and was done in the laboratory Pharmaceutical Laboratories UIN Makassar, then the making process of Demineralized Freeze-Dried Dentin Matrix (DFDDM) was done in Integrated Biotechnology Laboratory Animal Husbandry Faculty of Hasanuddin University, Makassar STIFA Research Laboratory, the guinea pig tooth was extracted and

application of materials at the socket is divided into 5 treatment groups based on days of observation, 7, 14, and 21 days. The first group was given dried Moringa leaf extract (MO) 2% (0.5-gram MO in 24-gram PEG). The second group was given 0.5-gram DFDDM. The third group was given a combination (0.5-gram MO, 0.5-gram DFDDM, and 24-gram PEG). Group IV was given a 0.5-gram Gamacha bone graft as a positive control and Group V was given polyglukol (PEG) as a negative control in mandibular incisor retraction socket. On the 7th, 14th and 21st days of observation, the guinea pig was sacrificed and Caviacobaya's mandible was taken

and stored in a 70% formalin solution. OPG and RANKL expression was observed by immunohistochemical polyclonal anti- OPG and anti-RANKL. Observation of the preparation and measurement of OPG RANKL expression was done with a light microscope, 1000x magnification. The Shapirowalik sample test was performed at the observation result to determine the normality of the distribution of the samples, after that the Levene test was performed to determine the homogeneity of the data, afterward, One-way ANOVA and Tukey HSD post hoc test was done to determine the differences between the study groups.

RESEARCH RESULT

Immunohistochemistry observation on the mandibular incisor extraction socket

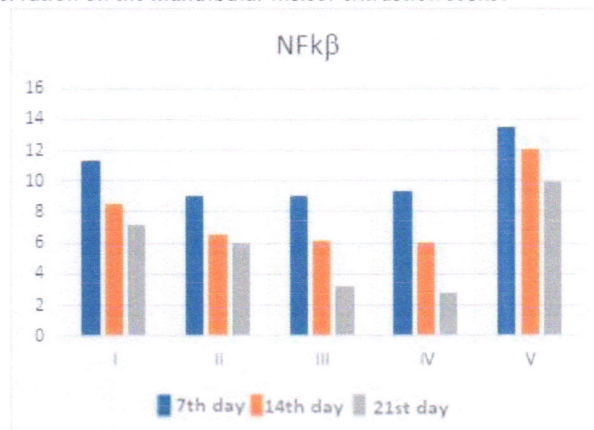


Figure 1: Graph of the average of NFκB expression on histological observation on the 7th, 14th, and 21st day

Based on Figure 1, Graph of the average of NFκB expression in immunohistochemical observation on the 7th, 14th, and

21st days, the entire group descriptively undergoes a mean decrease of the expression NFκB.

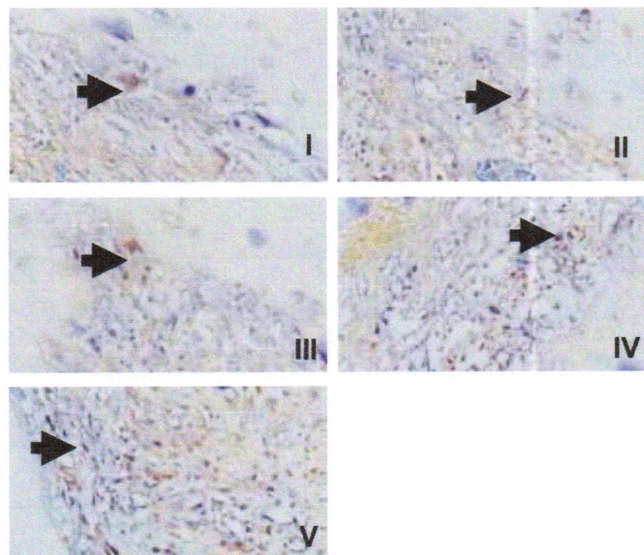


Figure 2: The arrows indicated the expression of NFκB at the Immunohistochemical observation on the 7th day at the group

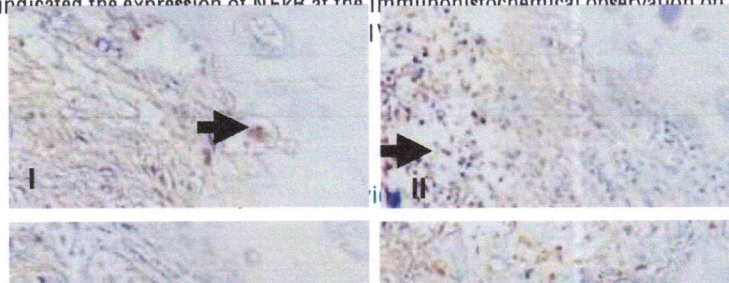


Figure 3: The arrows indicate the Expression of NFkB on immunohistochemical observation on the 14th day at the group I, II, III, IV, and V

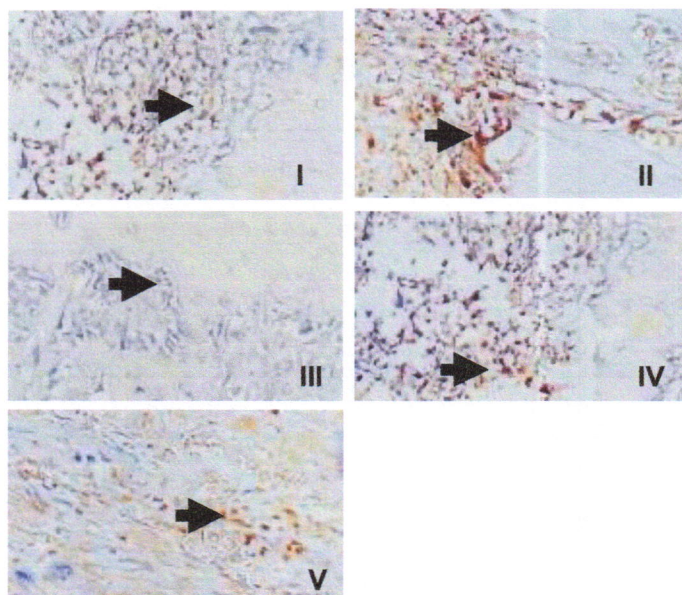


Figure 4: The arrows indicate the Expression of NFkB on immunohistochemical observation on the 21st day at the group I, II, III, IV, and V.

Table 1: The average of the NFkB expressions amount at the immunohistochemistry observation on the mandibular incisor extraction socket

Group	N	Observation	NFkB ($\bar{x} \pm SD$)	p Value
I	3	Day 7	9.00 ± 1.00	0.026*
	3	Day 14	6.50 ± 0.50	
	3	Day 21	6.00 ± 1.00	
II	3	Day 7	11.33 ± 2.08	0.011*
	3	Day 14	8.50 ± 0.50	

	3	Day 21	7.17	± 1.04	
III	3	Day 7	9.00	± 1.00	
	3	Day 14	6.17	± 1.04	0.002*
	3	Day 21	3.17	± 1.25	
IV	3	Day 7	9.33	± 1.52	
	3	Day 14	6.00	± 1.00	0.001*
	3	Day 21	2.83	± 0.76	
V	3	Day 7	13.50	± 1.50	
	3	Day 14	12.0	± 1.00	0.031*
	3	Day 21	10.0	± 1.00	

*OnewayAnova; p<0.05; significant

Based on table 1, the immunohistochemistry observation of the averageNFkB expression at the guinea pigs mandibular incisor extraction socket, showing the OnewayAnova test, looks across the treatment groups had a significant value of

p <0.05, which means there is a significant difference in each treatment group. Afterward, Tukey's Honest Significant Difference (HSD) test was done.

Table 2: Tukey's Honest Significant Difference (HSD) test at the expression average immunohistochemistry observations on the mandibular incisor extraction socket

Treatment Group	Observation	Comparison	p* NFkB Value
I	Day 7	Day 14	0.099
		Day 21	0.023*
	Day 14	Day 21	0.502
II	Day 7	Day 14	0.028*
		Day 21	0.013*
	Day 14	Day 21	0.768
III	Day 7	Day 14	0.046*
		Day 21	0.002*
	Day 14	Day 21	0.037*
IV	Day 7	Day 14	0.027*
		Day 21	0.001*
	Day 14	Day 21	0.034*
V	Day 7	Day 14	0.338
		Day 21	0.026*
	Day 14	Day 21	0.179

*Post Hoc Tukey HSD; p<0.05; significant

NFkBimmunohistochemical observations at the mandibular incisor extraction socket, Group II showed a significance value of p <0.05, which means there is a significant difference between the decreased expression of NFkB on the 7th and 14th days but showed a significant value of p > 0.05 on the 14th and 21st days, which means there is no significant difference. Group I and V, showed a significance value p > 0.05, which means there is no significant difference

between the increase of the NFkB expression on the 7th days and 14th and on the 14th and 21st days. In the third group that use the combination (0.5-gram MO, 0.5-gram DFDDM, and 24-gram PEG) and group IV that was given 0.5 grams Gamacca® bone graft, shows the significant value of p <0.05, which means there is a significant difference between the increase of NFkB expression on the 7th and 14th days and the 14th to 21st days.

Table 3: Tukey's Honest Significant Difference (HSD) test of the average expression on NFkBimmunohistochemical observation on the 7th day on the mandibular incisor extraction socket

Group	I	II	III	IV	V
I		0.360	0.360	0.498	0.426
II			1.000	0.998	0.025*
III				0.998	0.025*
IV					0.039*
V					

*Post Hoc Tukey HSD; p<0.05; significant

According to the table 3, further different test on the 7th days NFkB observations immunohistochemistry at the mandibular incisor extraction sockets shows the significant value of $P < 0.05$ in group V to group II, III, and IV on the day of observation to 7, which means there is a significant difference between the average difference in the number of expressions NFkB in group V to group II, III and IV, while

the significant value also shows the value of $p > 0.05$, which means there is no significant difference between the average difference in the number of expressions NFkB, the average difference expression NFkB between the treatment group, and the other one.

Table 4: Tukey's Honest Significant Difference (HSD) test of the average expression on NFkB immunohistochemical observation on the 14th day on the mandibular incisor extraction socket

Group	I	II	III	IV	V
I		0.092	0.044*	0.030*	0.003*
II			0.987	0.948*	0.000*
III				0.999	0.000*
IV					0.000*
V					

*Post Hoc Tukey HSD; $p < 0.05$; significant

Based on table 4, further different test on the 7th days NFkB observations immunohistochemistry at the mandibular incisor extraction sockets, Group I to Group III, IV, and V, as well as the group V to group I, II, III, and IV demonstrate the significant value of $p < 0.05$, which means there is a significant difference between the average difference in the

number of expressions NFkB, Or have a different effect. Other groups demonstrated a significant value of $p > 0.05$, which means there is no any significant difference between the average difference expressions NFkB or have the same effect between the treatment group and the other one.

Table 5: Tukey's Honest Significant Difference (HSD) test of the average expression on NFkB immunohistochemical observation on the 21st day on the mandibular incisor extraction socket

Group	I	II	III	IV	V
I		0.644	0.005*	0.003*	0.043*
II			0.045*	0.023*	0.005*
III				0.994	0.000*
IV					0.000*
V					

*Post Hoc Tukey HSD; $p < 0.05$; significant

Based on Table 5, further different test on the 21st days NFkB observations immunohistochemistry at the mandibular incisor extraction sockets, Group I to Group III and IV, Group II to Group III and IV, and group V to group III, and IV demonstrate the significant value of $p < 0.05$, which means there is a significant difference between the average difference in the number of expressions NFkB, or have a different effect. Other groups demonstrated a significant value of $p > 0.05$, which means there is no significant difference between the average difference expression NFkB or have the same effect between the treatment group and the other one.

DISCUSSION

This study aims to determine the effect of the combination of Moringaoleifera L. and DFDDM in improving the alveolar bone NFkB after tooth extraction in Caviacobaya. This research was conducted on experimental animals, Caviacobaya, because it has a similar immune response in humans¹³

Autogenous bone graft has been used to repair bone defects because dentin and bone have the main osteoinductive characteristic¹⁴, demineralized dentin matrix (DDM) an organic material obtained from the dentine has the osteogenic ability¹⁵ because containing bioactive molecules

of collagen type-I and its growth factors such as BMP-2 and fibroblast growth factors that contribute to osteoinduction and osteoconduction of human teeth as graft.¹⁶ Human teeth are rich sources of stem cells, matrix, trace metal ions, and growth factors. Although the structure of bone and dentin tissue is different, the ratio of the components is similar (70% minerals, 20% collagen, body fluids 10% of the weight). After demineralization, the main structure of the dentin matrix is collagen type-I (95%) and non-collagenous proteins such as growth¹⁷ The growth factors were identified in human dentin including insulin-like growth factor-I (IGF-I), skeletal growth factor / insulin-like growth factor II (IGF-II), and transforming growth factor- β (TGF- β)¹⁸

The results of this study showed the protein expression of nuclear factor kappa beta (NFkB) in immunohistochemical observation. In Table 1, immunohistochemical observation on the application of autograft material using Demineralized Freeze-Dried Dentin Matrix (DFDDM) on the 7th, 14th and 21st days showed a decrease in the expression of NFkB significant which obtained through OnewayAnova test at the DFDDM administration group. Bone Morphogenetic Protein (BMP) organic substance on DDM decreases the regulation of Runx2, a transcription factor that stimulates and coordinates the activity of osteoblasts. NFkB can inhibit the expression of bone matrix

proteins by reducing the expression associated with antigen-1-Fos (Fra1) which is a positive regulator of bone matrix protein transcription. NFkB gives a negative effect through the activation of noncanonical pathways, which involves the formation of a heterodimer consisting of RelB-p52.²⁰

NFkB plays a main role in the decreased matrix protein expression caused by an inflammatory condition, which eventually results in a bone formation decrease. The inhibition of NFkB activation through the expression of matrix proteins stimulated by Wnt and BMP involves direct interaction with the NFkB response elements in the promoter region of bone matrix proteins and the inhibition of β -catenin binding and Runx2 to closest consensus sites. Although NFkB usually regarded as a positive regulator of inflammatory cytokines, the inhibition effects mediated by the classical pathway (canonical).NFkB p65-p50 heterodimer than NFkB p50-p50 homodimer more common.NFkB capacity to suppress the expression of BSP and osteocalcin relies on the interaction of HDAC1-NFkB stimulated by TNF that causes NFkBdeacetylation and nuclear localization²⁰

The results of this study also showed an NFkB decrease on the 7th, 14th and 21st days of observation using the Oneway ANOVA test at the group with the extraction of Moringaoleifera leaves are shown in table 1. M. oleifera is a plant that is rich in protein, flavonoids, saponins, alkaloids, tannins, amino acids essential, also antioxidants, (Kou et al., 2018). Through antioxidants mechanisms, polyphenols have been shown to reduce the adverse effects of oxidative stress on osteoblasts through inhibition of TNF- α inducing apoptosis(Choi, 2012), Likewise, NFkB transcription or activation mediated by reactive oxygen. NFkB activation is triggered by the accumulation of reactive oxygen species(ROS), which resulted in the formation of superoxide free radicals. The antioxidant activity of the quercetin can bind to free radical species, therefore it reactivity decreases. The free radicals converted into a more stable form through a hydrogenation reaction, so it's unable to oxidize DNA. Thus, NFkBexpression decrease along with the antioxidant activity of quercetin on M. oleifera.

ROS is associated with oxidative stress which can induce cell apoptosis through mitochondrial dysfunction, resulting in damage to lipids, proteins, and DNA . Protein damage is the cause of the decreased expression of NFkB on immunohistochemical observations in this study. Through the antioxidants mechanism that is in line with studies conducted which prove that phytoestrogens increase the differentiation of MSCs and inhibit differentiation adipogenic through non-genomic mechanisms of ER-mediated.^{21,22,23,24}

M. oleifera has a therapeutic characteristic because of its anti-inflammatory activity potential of NFkB activation Induction of anti-inflammatory mediators by phytochemicals is important to avoid triggering the inflammatory cells because inflammation can lead to carcinogenesis through the activation of inflammatory mediators such as prostaglandins, cytokines, chemokines, and nitric oxide. Activation of the MAP-kinase family will also activate NFkB signaling that would cause inflammation. Therefore, the plant compound used for the treatment must

have the ability to inhibit mediators and signals. Previous research states that M. oleifera can provide an anti-inflammatory effect on male albino rat carrageenan-induced edema of the hind legs, and seed extract reported to reduce the weight of the distal intestine which is a marker for inflammation. In the experimental study of autoimmune encephalomyelitis (EAEC) with a mouse model, isothiocyanate (4 (α -L-rhamnosyloxy) -benzyl isothiocyanate) (GMG-ITC)) reduced levels of cytoplasmic protein when compared to the control mouse EAEC, ciplastin protein decreased after treatment, indicated that these compounds show anti-inflammatory effects on the cells, thus providing a protective effect against tissue of the central nervous system (CNS). Targeting molecular targets to inhibit the production of cyclooxygenase (COX) and nitrogen oxidase (NO) is a good way for inhibitors to show anti-inflammatory effects.

Based on table 1, osteoconductive and osteoinductive characteristics of the two ingredients above (the combination of M. oleifera and DFDDM) can reduce the amount of NFkB expression significantly on the 7th, 14th and 21st days of observation using One-way ANOVA test and the result provide the most excellent effect of other groups (Table 3-9). This study shows that the combination of DFDDM and M. oleifera can increase the amount of expression of OPG and RANKL expression and decrease the number of NFkB to the healing process after the revocation. This occurs by the presence of a combination of DFDDM and M. oleifera in socket preservation, autograft DFDDM have osteoinduction and DDM osteoconductive characteristic. (demineralized dentin matrix)¹⁵

Table 2 Tukey's Honest Significant Difference (HSD) test, group III with DFDDM and M. oleifera combination showed a significant increase in NFkB reduction on the observations on the 7th to 14th day, nor the 14th to 21st day. In contrast with another group, group I with the administration of M. oleifera and PEG which did not show any significant increase from the 14th to 21st days. The combination of these materials supports new bone formation which facilitated by DFDDM as a scaffold. Osteoconductive characteristics of DDM are in line with the research conducted by de Oliveira et al who did immunostaining BMP - 2 and BMP - 4 in osteoblasts during the healing process of the second molar sockets on mice that were applied with human DDM.¹⁵

Positive control at the Group IV with administration of Gamacha® bone graft material has approximately the same effect with the group II with DFDDM administration which has OPG increased on the 7th, 14th and 21st days, as well as an increase in further different test on the 7th to 14th days and on the 14th to 21st days (Table 3-9). Gamacha® bone graft materials have been used today. In contrast to DFDDM, Gamacha® only has good osteoconductive ability but has no osteoinductive and osteoproliferative characteristics. Group V with PEG administration is a negative group and didn't show any significant OPG increase and RANKL decrease.

CONFLICT OF INTEREST

There is no conflict of interest in this study

SOURCE OF FUNDING

Domestic Government

REFERENCES

1. Riskesdas. (2018). Basic Health Research 2018. Health Research and Development Agency of Health of the Republic of Indonesia.
2. Zarb, Hobkirk, Eckert, Jacob, Fenton, Finner, Chang, Koka. (2012). Prosthodontic treatment for edentulous patients; Complete denture and implant supported prostheses. 13th ed. St. Louis: MO: Mosby.
3. Kumar TA, Naeem A, Verma AK, Mariyam A, Krisna D, Kumar PK. (2016). Residual ridge resorption: the unstoppable" J app Res 2(2) :169- 17
4. Giele, H., and Cassel, O. (2008). Plastic and reconstructive surgery. Specialist handbook in surgery. Oxford: 41-47
5. Widyasari, Maulita R., Sadiyah., Ula, N. (2012). The Effect of Aloe Vera Extract Gel to the Amount of Fibroblas and Angiogenesis after Tooth Extraction. Faculty of Dentistry, GadjahMada University.
6. Carranza F. A., Henry H. T., Michael G. N. (2002). Clinical Periodontology 9 th ed. W. B. Saunders Co, Philadelphia.
7. Boyce, Brendan F, and Lianping Xing. (2008). "Functions of RANKL / RANK / OPG in Bone Modeling and Remodeling." 473: 139-46.
8. Venkatesan J, Kim S.K. (2010). Effect of temperature on isolation and characterization on
9. Bhattacharjya, Chayanika et al. (2016). "Tooth Derived Bone Graft Material." *World Journal of Dentistry* 7(1): 32-35.
10. Wang F, Xie C, Ren N, Bai S, Zhao Y. (2019). Human Freeze-dried Dentin Matrix as a Biologically Active Scaffold for Tooth Tissue Engineering. *J Endod* 45(11): 1321-1331.
11. Vergara-Jimenez, Marcela, Manal Almatrafi, and Maria Fernandez. (2017). "Bioactive Components in Moringa Oleifera Leaves Protect against Chronic Disease." *Antioxidants* 6(4): 91.
12. Krisnadi, ADudi. (2015). *Super nutrition of Moringa*. Morindo, Blora.
13. Kristiawati DI. (2017). Introduction A. Guinea Pig's Background. p. 1-3
14. Jain S, Agrawal N, Dwivedi A, Bajaj S. (2019). A modified technique for fabrication of custom-made afterload brachytherapy appliance. *J Indian Prosthodont Soc.* 19(1):79-82.
15. Bhattacharjya C, Gadicherla S, Kamath AT, Smriti K, Pentapati KC. (2016). Tooth derived bone graft material. *J Korean Assoc Oral Maxillofac Surg.* 7(1):32-5.
16. Joshi C, Dani N, Khedkar S. (2016). Alveolar ridge preservation using autogenous tooth graft versus beta-tricalcium phosphate alloplast: A randomized, controlled, prospective, clinical pilot study. *J Indian Soc Periodontol.* 20(4):429.
17. Murata M, Toshiyuki A, Masaharu M, Md Arafat K, In-Woong U, Yasuhito M, et al. (2013). Autograft of Dentin Materials for Bone Regeneration. *Adv Biomater Sci Biomed Appl* grafting.
18. Kabir MA, Murata M, Kusano K, Akazawa T, Shibata T. (2015). Autogenous Demineralized Dentin Graft for Third Molar Socket Regeneration - A Case Report. *Dentistry.* 5(11):11-4.
19. Tarapore, Rohinton S., et al. (2016). "NF- κ B has a direct role in inhibiting Bmp-and Wnt-induced matrix protein expression." *Journal of Bone and Mineral Research* 31.1. 52-64.
20. Achmad H, Oktawati S, Adam AM, Pasiga B, Sjahril R, Azizah A, Sukmana BI, Huldani, Siswanto H, Neormansyah I. (2020). Granulicatella adiacens bacteria isolation from periontital patients with polymerase chain reaction techniques. *Sys Rev Pharm.* 11(4): 394-400.
21. Horcajada M-N, Offord E. (2012). Naturally Plant-Derived Compounds: Role in Bone Anabolism. *Curr Mol Pharmacol.* 5(2):205-18.
22. Achmad, H. et al. (2018). Apoptosis Induction (Caspase-3,-9) and Human Tongue Squamous Cell Carcinoma VEGF Angiogenesis Inhibition using Flavonoid's Ethyl Acetate Fraction of Papua Ant Hill (Myrmecodiapendans). *Journal of International Dental and Medical Research.* 10(1): 276-84.
23. Djais Arni I, Thahir H, Hatta M, Achmad H, Wahyuni A. (2019). Differences of minimum inhibitory concentration (MIC) and minimum bacteridal concentration (MBC) of moringa leaf extract (*Morienga Oliefera L.*) on bacteria *Aggregaticateria Actionmycetecomitans* and *Porphyromans ginigivalis*. *IJPHRD.* 10(8).
24. Achmad H, Sri Ramadhany, Filipus Eric Suryajaya. (2019). Streptococcus Colonial Growth of Dental Plaque Inhibition Using Flavonoid Extract sof Ants Nest(Myrmecodiapendans): An in Vitro Study. *Pesquisa Brasileiraem Odontopediatria e ClinicaIntegrada.* 19(1):e4250.